Pigmentation: Too Much or Too Little?

Youwen Zhou, MD, PhD, FRCPC
Presented at the Annual Dermatology Update, February, 2006

There are many pathological processes that result in excessive or inadequate production of skin pigment. Since they often occur in highly visible areas of the skin, such as the face and neck and the exposed parts of the arms and legs, the impact on the personal well-being can be very significant.

The most common pigmentation disorders include:

- photoaging (solar lentigines and ephelides),
- melasma,
- post-inflammatory hyperpigmentation and
- vitiligo.

Although particularly a concern for people with darker skin tones, pigmentation abnormalities can occur in every ethnic group. Choosing appropriate therapies can improve or eliminate the pigmentation disorder and minimize the potential adverse events, such as additional undesirable iatrogenic hyperpigmentation or hypopigmentation that, if developed, can be refractory to further therapies.

Although particularly a concern for people with darker skin tones, pigmentation abnormalities can occur in every ethnic group.

Dr. Youwen Zhou is an Assistant Professor, Pigmentation and Vitiligo Clinic, Department of Dermatology and Skin Science, University of British Columbia, Vancouver, British Columbia.

Photoaging induced pigmentation

Ephelides (freckles) and solar lentigines typically occur on sun-exposed areas of the skin, such as the face, the dorsal hands and extensor sides of the arms. They present as well-demarcated macules or thin plaques. Freckles are smaller, with a diameter typically 1 mm to 3 mm. The border can be angular or stellate in shape. On the other hand, solar lentigines are larger, sometimes reaching in sizes > 1 cm in diameter. The border is usually smooth. The color for both freckles and solar lentigines is tan or light brown and homogeneous. The homogeneous nature of these lesions helps differentiate them from malignant melanoma and its precursors such as lentigo maligna. If the diagnosis is in doubt, biopsies should be performed. Since there is no risk of malignant degeneration, freckles and solar lentigines do no need treatment for medical reasons.

For cosmetic improvement, ablative therapies such as Q-switched (QS) lasers offer the best results with few adverse events, such as transient post-inflammatory hyperpigmentation. Intense pulsed light (IPL) therapy can also be effective. However, multiple treatment sessions are needed and there is a higher recurrence rate compared with QS lasers. Cryotherapy can be used in lighter-skinned individuals. However, for darker-skinned individuals, cryotherapy should be avoided because it can cause long lasting pigmentation irregularities.

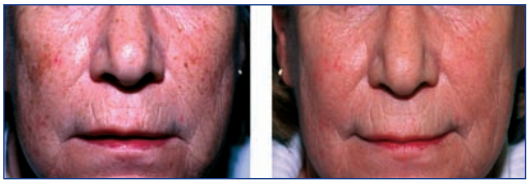

Figure 1. Before and after various ablative therapies.

Copyright © Not for Sale or Commercial Distribution
Unauthorized use prohibited. Authorized users can download, display, view and print a single copy for personal use

Melasma

Melasma occurs in as many as 10% of women and the incidence is even higher during and after pregnancy. Although rare, men can also develop melasma. It presents as brown-to-grey macules or patches most frequently on the malar regions of the cheeks. Other areas such as the forehead and the nose can also be affected. It is larger and less demarcated compared with ephelides and solar lentigenes. States of excess estrogen, such as pregnancy when taking OCs, as well as excessive sun exposure, can increase the severity of melasma pigmentation on the face.

States of excess estrogen, such as pregnancy and taking OCs, as well as excessive sun exposure, can increase the severity of melasma pigmentation on the face.

Melasma can be effectively treated with a combination of sun avoidance, sun protection and use of topical skin lightening agents such as hydroquinone-containing preparations. QS lasers, IPL and cryotherapy should be avoided, as they can cause a worsening of melasma pigmentation. Similarly, monobenzylether of hydroquinone should be avoided because it can result in permanent leukoderma.

Figure 2. Before and after various skin therapies.

Vitiligo

Vitiligo is an acquired depigmentation of the skin, resulting in porcelain white patches that can cause severe disfigurement of the affected individuals. The mechanism of pathogenesis is not understood. However, rarely it is associated with autoimmune disorders such as:

- thyroid disease,
- diabetes,
- anemia and
- adrenal insufficiency.

The most widely used therapy is topical immune suppressants, such as corticosteroid and calcineurin inhibitors. Children are more responsive than adults to topical therapies. In patients who have no adequate response to topical therapies, or the involved areas are widespread, phototherapy with narrow-band (NB) UVB can result in significant repigmentation in more than 50% of patients after six months to 12 months of therapy. Administered in specialized treatment centers, NB-UVB has largely replaced psoralen (P) and UVA as the phototherapy of choice for vitiligo due to recently documented cancer risk increase associated with prolonged PUVA. In recalcitrant cases, autologous epidermal grafting can induce repigmentation for some patients. For many patients, use of artificial skin tanning agents that stain the affected skin areas brown can achieve effective camouflaging for as long as one week to two weeks after each application.

The dihydroxyacetone contained in these preparations stains the epidermal keratin layers of the skin, which are eventually shed away in one week to two weeks, requiring another application of the staining preparation.

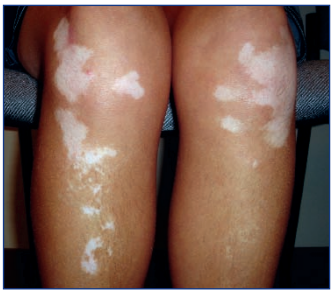

Figure 3. Vitiligo on legs.

Post-inflammatory hyperpigmentation (PIH)

When skin wounding or inflammation clears, it often leaves darker pigmentation. The common causes of PIH include:

- acne and other skin inflammation states,
- inappropriate use of facial cosmetics and
- cosmetic procedures.

Effective treatment of the underlying skin inflammation can reduce the occurrence of PIH.

The common causes of PIH include acne and other skin inflammation states, inappropriate use of facial cosmetics and cosmetic procedures.

Selecting the most appropriate cosmetic procedures for patients prone to develop PIH can also reduce severe PIH in patients with darker skin tone. Fortunately, most cases of PIH resolve spontaneously with sun protection in a few months. No specific treatment is required.

Figure 4. PIH on forearm.

Take-home message

1. It is essential to exclude malignant melanoma and its precursors before treating any pigmented skin lesions
2. Photoaging induced skin pigmentation, such as ephelides and solar lentigines are best treated with ablative lasers
3. Melasma requires both photo protection and topical depigmentation preparations. Maintenance therapy is usually required for long term therapeutic effect
4. Post-inflammatory hyperpigmentation usually resolves spontaneously and generally requires no specific therapy
5. Patients with vitiligo require clinical and/or laboratory assessment of other autoimmune disorders. Although complete repigmentation is rare, significant response can be achieved with topical steroids, calcineurin inhibitors or phototherapy

cme

References
1. Ortonne JP, Pandya AG, Lui H, et al: Treatment of solar lentigines. J Am Acad Dermatol 2006; 54(5 Suppl 2):S262-71.
2. Rendon M, Berneburg M, Arellano I, et al: Treatment of melasma. J Am Acad Dermatol 2006; 54(5 Suppl 2):S272-81.